

Tuberculous cervical lymphadenitis after BCG immunotherapy for bladder cancer

A case report and review of the literature

Serafeim-Chrysovalantis Kotoulas¹,
Katerina Manika²,
Georgios Piliandis³,
Paulos Tsikouriadis⁴,
Georgios Kalopitas³,
Nikolaos Petridis³,
Athanasia Apsemidou³,
Iakovos Avramidis³

¹Respiratory Failure Unit,

²Pulmonary Department, Medical School,
Aristotle University of Thessaloniki,

³Internal Medicine Department,

⁴Radiology Department,
G. Papanikolaou Hospital, Thessaloniki, Greece

Key words:

- Bacille Calmette-Guerin
- Bladder cancer immunotherapy
- Cervical lymphadenitis
- Abscess
- Lemierre's syndrome

Abbreviations

BCG: Bacillus Calmette-Guérin
CT: computed tomography

Correspondence:

Serafeim-Chrysovalantis Kotoulas,
Resident of Respiratory Medicine,
Respiratory Failure Unit, "G. Papanikolaou" General
Hospital, Thessaloniki, Greece,
105 Agiou Stefanou street, 57010 Pylaia – Chortiatis,
Thessaloniki, Greece
Tel.: +30 2313307178, Fax: +30 2313307253
E-mail: akiskotoulas@hotmail.com

ABSTRACT

Since its introduction in 1976, Bacille Calmette-Guerin (BCG) has become the standard of care in high risk non-muscle-invasive bladder cancer. Apart from its efficacy, BCG immunotherapy is also considered to be safe. However, in addition to its common adverse effects, which are mild, it can rarely cause serious adverse effects, which can be life threatening. In this report, the case of an 85-year old male, who developed tuberculous cervical lymphadenitis and abscess after BCG immunotherapy is described. The patient presented with acute renal failure. During his hospitalization he also developed hepatitis because of the anti-tuberculous therapy and eventually passed away, probably by septic emboli originated from his right jugular vein which was infiltrated by his abscess. Tuberculous cervical lymphadenitis accompanied with abscess is a quite rare complication of BCG immunotherapy, but clinicians should be aware of it, as it can be proved fatal.

Pneumon 2020, 33(3):143-147.

INTRODUCTION

Bacillus Calmette-Guérin (BCG), apart from vaccine for Tuberculosis, can also serve as a bladder cancer immunotherapeutic vaccine.¹ When BCG is infused into the urinary bladder, it causes an inflammatory reaction with monocyte infiltration and class-II major histocompatibility complex expression in malignant cells. Subsequently, the malignant cells are targeted by lymphokine-activated killer cells and BCG antigen-presenting cells.² BCG immunotherapy for bladder cancer is not only effective but also safe, since its most common adverse effects are easily manageable. However, some more serious, but uncommon, adverse reactions have also been reported. To date, limited cases of tuberculous lymphadenitis following BCG immunotherapy for bladder cancer have been reported³ and to the best of our

knowledge cervical lymph nodes were involved in only one case that was treated successfully.⁴ We report a case of an 85-year old male, who developed tuberculous cervical lymphadenitis and abscess after BCG immunotherapy for bladder cancer and eventually died.

CASE REPORT

The patient presented with acute renal failure [Urea:224mg/dl, Creatinine: 4.39mg/dl], while his baseline creatinine level was about 1.50mg/dl. From his recent history, he presented an abscess in his right cervix, which had appeared ten days earlier, accompanied with low fever. Three days later, he had been subjected to surgical drainage of the abscess and had received antibiotic therapy with Amoxicillin/Clavulanic. From his past history, he presented type II diabetes mellitus and bladder papillomas, while twelve months before, he had developed bladder cancer for which he had been treated with BCG immunotherapy.

On admission, his white blood cells were normal [8.420/ μ L (62.0% neutrophils, 24.6% lymphocytes)] and his arterial blood gases were pH=7.42, PaCO₂=31.6mmHg, PaO₂=67.2mmHg and HCO₃⁻=19.8mEq/L on room air, while his c-reactive protein was elevated (9.14mg/dl). Treatment with fluids was initiated for his renal failure and low blood pressure (85/55mmHg). Intravenous antibiotic therapy for his abscess with Piperacillin/Tazobactam was also initiated while pus from the abscess was sent for culture. A neck ultrasound revealed multiple swollen lymph nodes which maintained their shape and vascularization, in a phase of acute inflammation, accompanying a spindle-like, sub-sounded inflammatory region, with increased anarchic internal vascularization, ending in a tube-like outgrowth beneath the skin like fistula (Figures 1a–b).

Four days later, the patient's blood pressure was stabilized, his renal function improved, maintaining a continuous diuresis, but his low fever persisted, while his pus culture was negative for common bacteria. Thus, a neck computed tomography (CT) was performed, which showed swollen lymph nodes with central melting and the abscess, surrounding the patient's right jugular vein, which appeared fine-spun (thin with decreased inner diameter) with a lack of repletion after contrast agent infusion, an image that set the suspicion of tuberculous lymphadenitis and of right jugular vein thrombosis (Figure 2). Therefore, a new pus sample was collected from his abscess and sent for Xpert MTB/RIF assay (Cepheid,

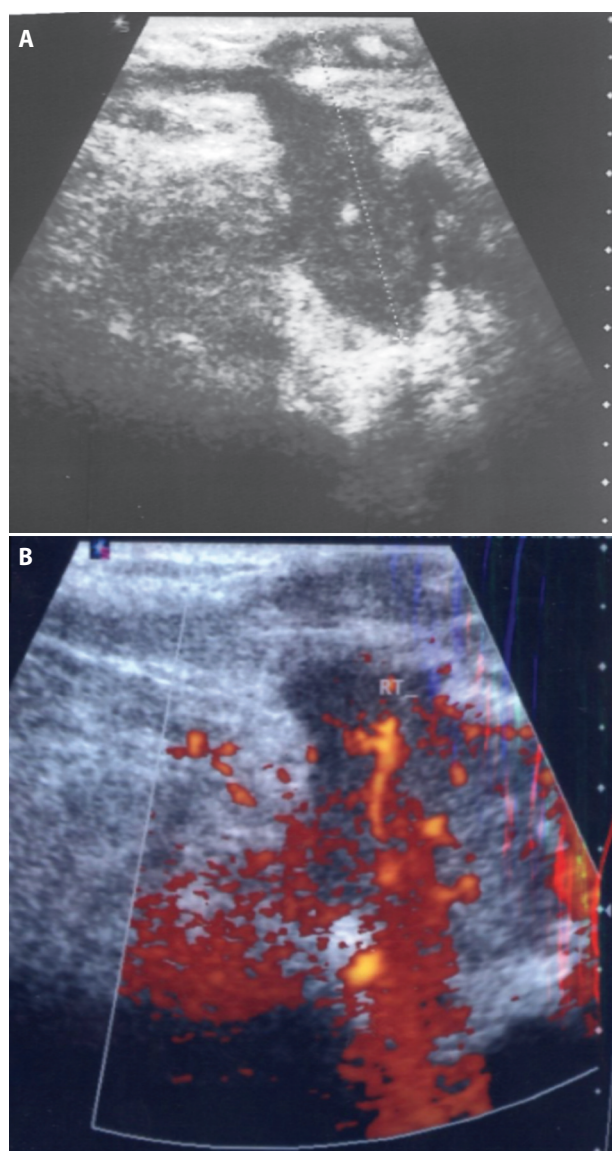


FIGURE 1A – B. Neck ultrasound revealing multiple swollen lymph nodes, maintaining their shape and vascularization, in a phase of acute inflammation, accompanying a spindle-like sub-sounded inflammatory region, with increased anarchic internal vascularization, ending in a tube-like outgrowth beneath the skin like fistula.

Sunnyvale, California, USA), acid fast staining and culture for mycobacteria, something that was not done with the first sample. The new sample was positive for *Mycobacterium Tuberculosis* complex nucleic acid and resistance to Rifampicin was not detected. Acid fast staining was negative. Having optimized the patient's renal function, his antibiotic therapy with Piperacillin/Tazobactam was

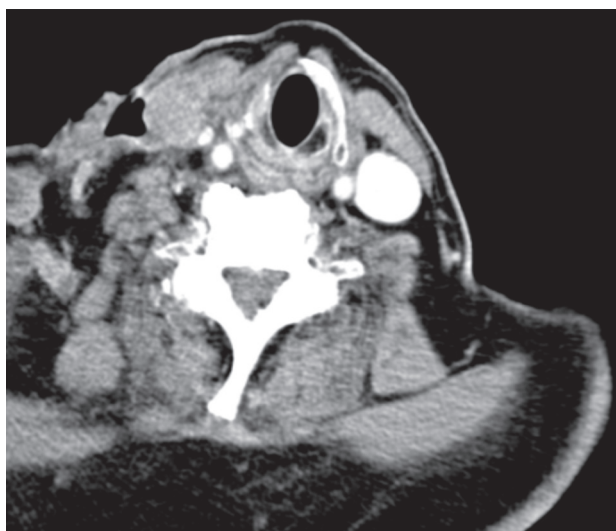

FIGURE 2. Neck CT revealing swollen lymph nodes with central melting and the abscess, surrounding the patient's right jugular vein, which appeared fine-spun (thin with decreased inner diameter) with a lack of repletion after contrast agent infusion, an image that set the suspicion of tuberculous lymphadenitis and of right jugular vein thrombosis.

stopped and standard anti-tuberculosis treatment (Isoniazid, Rifampicin, Pyrazinamide and Ethambutol) was initiated. A chest CT was also performed, which did not reveal any signs of active or past pulmonary tuberculosis. Furthermore, the patient was not aware of coming in close contact with any person having pulmonary tuberculosis in the past, while before his BCG immunotherapy, he was subjected to Mantoux test, which was negative. His close relatives were also checked with Mantoux test and were all negative. Because of his recent history, BCG immunotherapy was considered to be responsible for the patient's tuberculous lymphadenitis. Unfortunately molecular confirmation was not possible. The culture of the last pus sample also came back positive for the *Mycobacterium Tuberculosis* complex six weeks later. Although the subtype of the *Mycobacterium* could not be identified, the strain was resistant to Pyrazinamide.

Nine days after anti-tuberculous treatment initiation, the patient developed transaminasaemia and hyperbilirubinemia, which were attributed to the anti-tuberculous regimen. Treatment was discontinued and the liver biochemistry profile started to improve. However six days later and before reinitiation of treatment, the patient presented acute chest pain with dyspnea and developed a rapidly evolving type I respiratory failure with respira-

tory alkalosis and a respiratory rate of 34 breaths/min. He also showed hemodynamic instability unresponsive to fluid and vasopressor therapy. Having not presented elevated troponin levels, changes in his electrocardiogram compared to that of his admission, apart from tachycardia (132 beats/minute), or any other pathological findings, it was suspected that the patient suffered from septic emboli originating from his right jugular vein, which was infiltrated by his abscess. However, CT Pulmonary Angiogram was not performed due to the patient's rapid deterioration and eventual death within one hour.

DISCUSSION

Since its introduction in the treatment of high risk non-muscle-invasive bladder cancer, BCG has become the standard of care.¹ BCG immunotherapy has been shown to be an effective treatment for the superficial bladder carcinoma, since its efficacy in the prevention of recurrence is estimated at 70-99%, which is higher than for local chemotherapy.⁵ Despite the adverse effects that have been reported, it is generally considered to be safe, since its most common adverse effects, such as cystitis (>90% of adverse effects), fever (2.9%), hematuria (1%), prostatitis (0.9%), and arthralgia or arthritis (0.5%), are mild and non-life-threatening.⁶ However, serious adverse events such as spondylitis with adjacent mycotic aortic aneurysm, spondilodiscitis with medullary and spinal abscess, granulomatous pneumonia, tuberculous epididymitis, parotid tuberculosis and miliary tuberculosis have also been reported.⁵⁻¹⁰ Organ inflammation after BCG immunotherapy is considered to be caused through hematogenous spread.⁵ In the only case of cervical lymphadenitis after BCG treatment for bladder cancer that has been reported in the literature, the age of the patient was 68 years and the infection occurred two years after BCG treatment,⁴ whereas in the case presented here, the patient was 85 years old and the infection developed one year after his BCG treatment. Immunocompromisation and higher age are considered risk factors for complications by BCG immunotherapy. Patients younger than 70 years have a risk of complications at 17.6%, while for those who are 70 years or older the respective risk is at 48.6%.¹¹ In this case, the patient was older than 70 years old and had diabetes, a condition that causes immune deficiency.

The main limitation of this case report is the inability to identify BCG from culture. Nevertheless, there were many factors that indicated a BCG infection. First of all, the

recent BCG immunotherapy that the patient received for his bladder cancer. Secondly, the lack of history of exposure based on his negative mantoux test and thirdly the absence of signs of active or past pulmonary tuberculosis in the chest CT scan. Most importantly the isolated strain was resistant to Pyrazinamide and BCG is typically resistant to Pyrazinamide. Since monoresistance to pyrazinamide is not common for "typical" tuberculosis this finding along with the patient's history may be considered as an indirect confirmation of BCG. It is also worth mentioning, that there are several cases of suspected BCG infection after treatment for bladder cancer in the literature, in which identification of BCG was not possible.^{5,12-16} According to a 2014 review, in BCG suspected infections after BCG bladder treatment, acid-fast staining, mycobacterial culture and PCR-based assays were only positive in 25.3%, 40.9%, and 41.8% of cases, respectively.¹⁷ The higher sensitivity of PCR and culture can explain the negative acid fast staining observed in the present case.

Another limitation of this case is the patient's unidentified cause of deterioration and death. Transaminasaemia and hyperbilirubinemia, which forced the discontinuation of the anti-tuberculous therapy, were probably caused by the combination of three hepatotoxic drugs. His acute chest pain, accompanied by dyspnea, tachypnea and rapidly evolving type I respiratory failure with respiratory alkalosis and his severe hemodynamic instability, are common in pulmonary embolism. The findings of his neck CT, showing a fine-spun right jugular vein, with lack of repletion after contrast agent infusion, surrounded by the abscess, set the suspicion of Lemierre's syndrome, since there were no other pathological findings indicating an alternative diagnosis. Septic emboli due to tuberculous pathogens are rare,¹⁸ and

so is the Lemierre's syndrome. Lemierre's syndrome is the infectious thrombophlebitis of the internal jugular vein, which may lead to further systemic complications such as septic emboli. In a 2020 systematic review of Lemierre's syndrome, there were no cases of the syndrome that were caused by tuberculous pathogens,¹⁹ something that also reflects the findings of earlier systematic reviews. To our knowledge there is only one published case, in which the syndrome was caused by a coinfection by *Levinea* sp and *Mycobacterium tuberculosis*.²⁰

This is the first case of tuberculous cervical lymphadenitis after BCG immunotherapy for bladder cancer that proved lethal. Clinicians should always suspect Tuberculosis in a patient with infection after BCG immunotherapy for bladder cancer, regardless the localization of the infection, and act timely, in order to diagnose and treat it, taking into account the various complications that could emerge in the process.

ACKNOWLEDGEMENTS

This research did not receive any specific grant from funding agencies in the public, commercial, or not-for-profit sectors.

CONFLICT OF INTEREST

None.

FUNDING

This research did not receive any specific grant from funding agencies in the public, commercial, or not-for-profit sectors.

ΠΕΡΙΛΗΨΗ

Φυματιώδης τραχηλική λεμφαδενίτιδα μετά από ανοσοθεραπεία με BCG για καρκίνο της ουροδόχου κύστης. Περιγραφή ενός περιστατικού και ανασκόπηση της βιβλιογραφίας

Σεραφείμ-Χρυσοβαλάντης Κωτούλας¹, Αικατερίνη Μανίκα², Γεώργιος Πηλιανίδης³,
Πάυλος Τσικουριάδης⁴, Γεώργιος Καλοπίτας³, Νικόλαος Πετρίδης³,
Αθανασία Αψεμίδου³, Ιάκωβος Αβραμίδης³

¹Μονάδα Αναπνευστικής Ανεπάρκειας, ²Πνευμονολογικό Τμήμα, Ιατρική σχολή, Αριστοτέλειο Πανεπιστήμιο Θεσσαλονίκης, Γ.Ν.Θ. "Γ. Παπανικολάου", Θεσσαλονίκη, ³Παθολογική Κλινική,

⁴Ακτινολογικό τμήμα, Γ.Ν.Θ. "Γ. Παπανικολάου", Θεσσαλονίκη

Υπόβαθρο: Από την εισαγωγή του σαν θεραπεία το 1976, ο βάκιλος *Calmette-Guerin* (BCG) έχει γίνει η πρότυπη θεραπεία σε υψηλού κινδύνου μη-διηθούντες τους λείους μύες (εσωτερικής επιφάνειας) καρκί-

νους της ουροδόχου κύστης. Εκτός από την αποτελεσματικότητα της η ανοσοθεραπεία με BCG θεωρείται επίσης και ασφαλής. Παρόλα αυτά, επιπρόσθετα στις πιο κοινές ανεπιθύμητες ενέργειες της, οι οποίες είναι ήπιες, μπορεί σπανίως να προκαλέσει σοβαρές ανεπιθύμητες ενέργειες, οι οποίες μπορεί να είναι απειλητικές για τη ζωή. **Μέθοδοι:** Σε αυτό το άρθρο, περιγράφεται το περιστατικό ενός 85-χρονου άνδρα, ο οποίος ανέπτυξε τραχηλική λεμφαδενίτιδα και απόστημα, μετά από ανοσοθεραπεία με BCG ένα χρόνο νωρίτερα.

Αποτελέσματα: Ο ασθενής παρουσιάστηκε με οξεία νεφρική ανεπάρκεια, που προκλήθηκε από το απόστημα του. Κατά τη νοσηλεία του ανέπτυξε επίσης και ηπατίτιδα λόγω της αντιφυματικής του αγωγής και τελικά πέθανε πιθανώς από σηπτικά έμβολα που προήλθαν από τη δεξιά Σφαγίτιδα φλέβα του, που είχε διηθηθεί από το απόστημά του. **Συμπεράσματα:** Η φυματιώδης τραχηλική λεμφαδενίτιδα που συνοδεύεται από απόστημα είναι μια σχετικά σπάνια επιπλοκή της ανοσοθεραπείας με BCG, αλλά οι κλινικοί γιατροί θα πρέπει να είναι ενήμεροι για αυτήν, καθώς μπορεί να αποδειχθεί θανάσιμη.

Πνεύμων 2020, 33(3):143-147.

Λέξεις - Κλειδιά: Βάκιλος Calmette-Guerin, ανοσοθεραπεία καρκίνου ουροδόχου κύστης, τραχηλική λεμφαδενίτιδα, απόστημα, σύνδρομο Lemierre

REFERENCES

- Paterson DL, Patel A. Bacillus Calmette-Guerin (BCG) immunotherapy for bladder cancer: review of complications and their treatment. *Aust N Z J Surg* 1998; 68:340-4.
- Newman JR, Clough LA, Merino F. Mycobacterium bovis osteomyelitis of the thoracic spine mimicking a metastatic lytic lesion in a patient exposed to Intravesicular Bacille Calmette-Guérin treatment. *Urol Case Rep* 2014; 2:142-4.
- Xie J, Codd C, Mo K, He Y. Differential Adverse Event Profiles Associated with BCG as a Preventive Tuberculosis Vaccine or Therapeutic Bladder Cancer Vaccine Identified by Comparative Ontology-Based VAERS and Literature Meta-Analysis. *PLoS One* 2016; 11:e0164792.
- Geldmacher H, Taube C, Markert U, Kirsten DK. Nearly fatal complications of cervical lymphadenitis following BCG immunotherapy for superficial bladder cancer. *Respiration* 2001; 68:420-1.
- Rogoziński P, Taracha-Guz D, Pęcikiewicz P, et al. Granulomatous pneumonia as a complication of intravesical BCG immunotherapy—a case report. *Pneumonol Alergol Pol* 2014; 82:163-9.
- Kusakabe T, Endo K, Nakamura I, et al. Bacille Calmette-Guérin (BCG) spondylitis with adjacent mycotic aortic aneurysm after intravesical BCG therapy: a case report and literature review. *BMC Infect Dis* 2018; 18:290.
- Lara-Oya A, Ramírez-Taboada J, Arenas-Miras Mdel M, Rodríguez-Granger J. Spondylodiscitis with medullary and spinal abscess caused by Bacillus Calmette-Guérin (BCG). *Rev Chilena Infectol* 2015; 32:706-9.
- Ishizu K, Hirata H, Yano S, et al. Tuberculous epididymitis caused by intravesical BCG therapy: a case report. *Hinyokika Kyo* 2003; 49:539-42.
- Díaz C, Baldó C, Martín A, et al. Parotid tuberculosis following intravesical BCG instillation: a case report. *Acta Otorrinolaringol Esp* 2003; 54:129-33.
- Arrese M, Ebel L, Hofmann E, et al. Miliary tuberculosis as a complication of BCG immunotherapy in cancer of the bladder. Case report. *Rev Med Chil* 1992; 120:910-3.
- Samadian S, Phillips FM, Deeab D. Mycobacterium bovis vertebral osteomyelitis and discitis with adjacent mycotic abdominal aortic aneurysm caused by intravesical BCG therapy: a case report in an elderly gentleman. *Age Ageing* 2013; 42:129-31.
- Dogan D, Zor M, Ozkisa T, Ayten O, Yigit N, Yavas I. Mediastinal granulomatous lymphadenitis after intravesical bacillus Calmette-Guerin treatment mimicking distant metastasis of primary bladder carcinoma. *Arch Bronconeumol* 2015; 51:526-7.
- Coddington ND, Sandberg JK, Yang C, Sehn JK, Kim EH, Strobe SA. Mycotic Aneurysm after Bacillus Calmette-Guérin Treatment: Case Report and Review of the Literature. *Case Rep Urol* 2017; 2017:4508583.
- Ye HY, Xu QQ, Huang XB, Ma K, Wang XF. Tuberculous prostatic abscess following intravesical bacillus Calmette-Guerin immunotherapy: a case report. *Beijing Da Xue Xue Bao Yi Xue Ban* 2015; 47:1039-41.
- Parker SG, Kommu SS. Post-intravesical BCG epididymo-orchitis: Case report and a review of the literature. *Int J Surg Case Rep* 2013; 4:768-70.
- French CG, Hickey L, Bell DG. Caseating granulomas on the glans penis as a complication of bacille calmette-guérin intravesical therapy. *Rev Urol* 2001; 3:36-8.
- Pérez-Jacoiste Asín MA, Fernández-Ruiz M, López-Medrano F, et al. Bacillus Calmette-Guérin (BCG) infection following intravesical BCG administration as adjunctive therapy for bladder cancer: incidence, risk factors, and outcome in a single-institution series and review of the literature. *Medicine (Baltimore)* 2014; 93:236-54.
- Vu K, Adler H, Gibbons E, Pearson J, Betz W. Intracerebral tuberculomas: A rare cause of seizure in an immunocompetent young male. *IDCases* 2019; 18:e00599.
- Moretti M, De Geyter D, Goethal L, Allard SD. Lemierre's syndrome in adulthood, a case report and systematic review. *Acta Clin Belg* 2020; 29:1-11.
- Salami A, Assouan C, Garba I, Konan E. An unusual cause of Lemierre Syndrome. *J Stomatol Oral Maxillofac Surg* 2019; 120:358-60.